



## Case Report:

### Stokes - Adams syndrome, not to confuse as hypoglycaemic syncope in diabetes. A case report.

Keshav Budhathoki<sup>1</sup>, Shyam Raj Regmi<sup>2</sup>, Sudhir Regmi<sup>2</sup>, Bishnu Mani Dhital<sup>2</sup>, Anand GC<sup>2</sup>, Sabina Sedhai<sup>2</sup>

<sup>1,2</sup> Department of Cardiology, Chitwan Medical College and Teaching Hospital, Bharatpur, Chitwan, Nepal.

#### Address for Correspondence:

Keshav Budhathoki  
Department of Cardiology  
Chitwan Medical College and Teaching Hospital  
Bharatpur, Chitwan, Nepal.  
E-mail: [keshavbudhathoki@gmail.com](mailto:keshavbudhathoki@gmail.com)

## Abstract

Stokes - adams syndrome is defined as abrupt, transient loss of conscious due to sudden and pronounced decrease in the cardiac output which is caused by sudden change heart rate or rhythm. Transient loss of consciousness is a common chief complaint of patients presenting to an Emergency Department. It comprises a heterogeneous group of disorders including epileptic seizures and various types of syncope. This definition does not include vasovagal syncope or epilepsy although patients with stokes-adams syndrome may have seizures during periods of cerebral ischemia. During the attack, there is an initial pallor followed by facial flush due to reactive hyperemia following resumption of normal circulation. Typically, complete heart block is seen on the ECG during an attack. The condition is usually associated with coronary heart disease and so tends to occur in the elderly.

**Key Words:** Diabetes mellitus, Syncope, Stokes-adams syndrome, Permanent pacemaker implantation

## Introduction:

Stokes adams syndrome is defined as an abrupt transient loss of consciousness due to sudden and pronounced decrease in the cardiac output which is caused by a sudden change in rhythm or heart rate<sup>1</sup>. It comprises a heterogeneous group of disorders, including epileptic seizures and various types of syncope<sup>2</sup>. It does not include vasovagal syncope or epilepsy but stokes adams syncope can have feature of seizure due to cerebral ischemia. Many arrhythmias can produce syncopal attack with or without

previously established complete heart block. The clinical feature of arrhythmia induced syncope depends upon the duration and type of underlying arrhythmia as well as status of the cerebral perfusion. The symptoms of arrhythmias induced syncope vary from slight faintness to loss of consciousness with or without seizure<sup>3</sup>. Initially during the attack, there is pallor followed by resumption of normal circulation manifested as facial flush due to reactive hyperemia. It usually starts and terminate abruptly. The patient may resume activity without being aware of the paused produced by period of arrhythmia induced cerebral hypoxia<sup>4</sup>. Electrographic monitoring during a syncopal period demonstrate the responsible rhythm and helps in providing appropriate therapy. Most patient with arrhythmia induced syncope have some impairment of atrioventricular conduction either during or between attacks. The ECG will show complete heart block, high grade AV block, or other malignant arrhythmia during the attacks. Torsades de Pointes can occur in a heart block setting<sup>5</sup>. The cause of stokes adams syncope is due to complete heart block. Adams-Stokes syndrome is most frequent above fifty years of age but about 30 per cent of the patients had their first attack below fifty. Coronary heart disease dominated as an etiologic factor.

Hypoglycemia is a well-known cause of coma which can be resolved by glucose infusion and is thus the opposite of syncope which is characterized by transient loss of consciousness (LOC) followed by spontaneous recovery<sup>6,7</sup>. Symptoms characteristic of hypoglycemia may include the following: blurred vision, drowsiness, short-term memory loss, attention deficit or difficulty concentrating, defective psychomotor skills, numbness, impaired ability to remain awake, neurological focalities and seizures<sup>8</sup>. Clinically, transient loss of consciousness during hypoglycemia appears similar to vasovagal syncope. Hypoglycemic syncope is uncommon, affecting 1.9% of diabetic patients using insulin therapy. It is characterized clinically by brief periods of unconsciousness with slow recovery and without loss of postural muscle tone. Hypoglycemic syncope is the most common metabolic syncope, with a reported incidence of 0.6% in diabetic patients and 4% in diabetic patients who are on insulin therapy<sup>9</sup>.

### **Case Presentation:**

A 74 years female presented with multiple episodes of loss of consciousness at home, each lasting for few seconds to minute. She was immediately taken to nearby local hospital but on the way to local hospital, she again developed loss of consciousness lasting for about a minute. At hospital emergency department itself, she developed two episodes of loss of conscious lasting about few seconds witnessed by treating doctor and other medical staffs. During the time of loss of consciousness, she become pale and cyanosed. Immediately ECG was done which showed Complete Heart Block with ventricular rate of 20bpm and was given one ampoule of atropine injection and asked to go to higher center hospital with cardiac facility. So came to our hospital for further management.

On arrival to our Emergency department, she was slightly drowsy and not responding appropriately. ECG monitor was connected to the patient which showed complete heart block with ventricular rate of 19-20bpm. She was given one ampoule of atropine injection immediately. As atropine injection did not work then started giving isoprenaline infusion. Then immediately transferred to CATHLAB for temporary pacemaker insertion and Coronary angiography. Coronary angiogram came out to be

normal. So, she was transferred to CCU with temporary pacemaker in situ and was doing well since two years and is under regular follow up.

She was a known case of hypertension and Diabetes since 15 years and was under oral medication that is Linagliptin 5mg, Metformin 500mg and Losartan with Hydrochlorothiazide. On physical examination, she was slightly drowsy with SPO<sub>2</sub> 87%. BP was unrecordable but pulse 22bpm, Irregular. Her blood report were normal including her cardiac enzymes report but her random blood sugar level was 355mg. Her blood sugar was managed with insulin infusion. Next day, Single chamber permanent pacemaker implantation was done and got discharged 6 days later without any uneventful events during hospital stay.

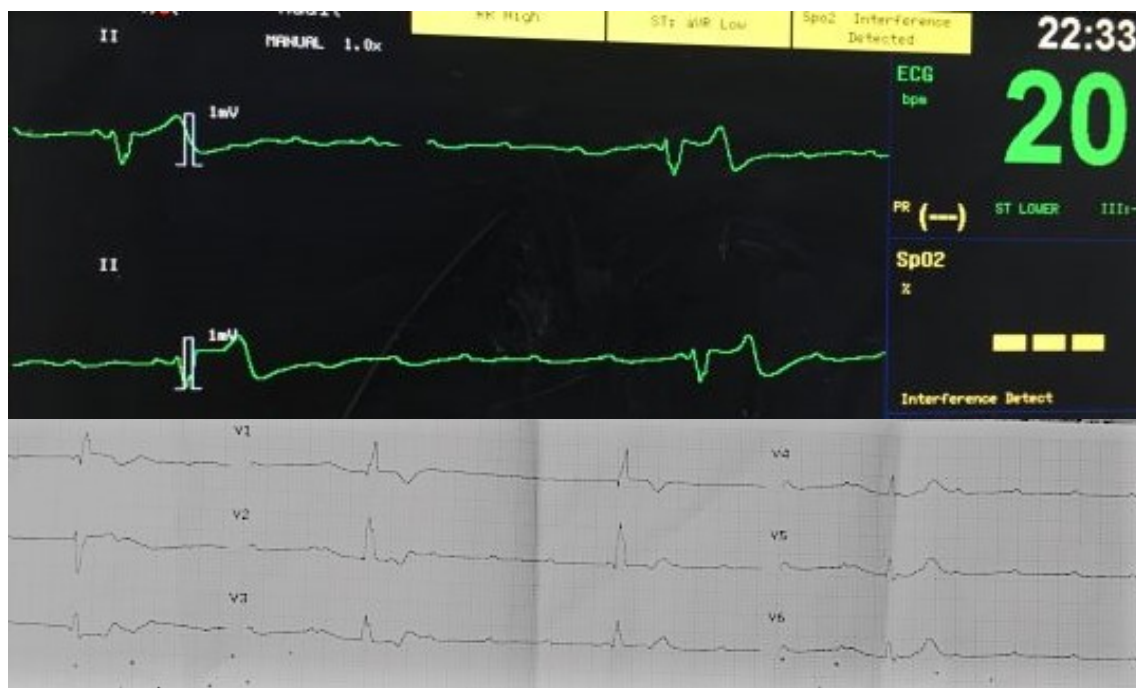

Fig 1 Complete Heart Block with Ventricular Rate of 20bpm.

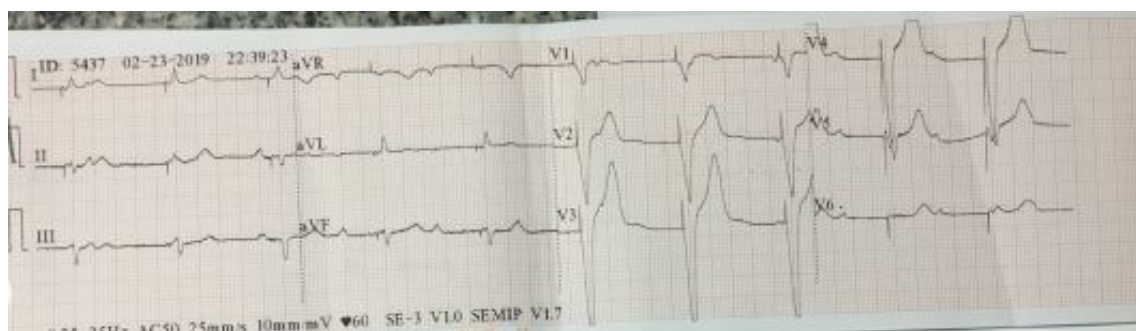


Fig 2 Complete Heart Block with Ventricular Pacemaker Rate of 60bpm.

### Discussion

Third-degree AV block is defined as the sudden and unexpected repetitive block of the atrial impulse on its way to the ventricle with consequent asystolic ventricular pause due to delayed emergence of a satisfactory escape rhythm. It is a known cause of syncope and potentially sudden cardiac death which may be prevented, if promptly diagnosed and treated with permanent pacemaker implantation<sup>11</sup>. Intrinsic AV block due to an

intrinsic disease of the AV conduction system usually occurs in patients older than 60 years. Electrocardiographically, the sudden onset of AV block explains why prodromes are absent or shorter than 3 seconds as in the present case. Stokes adams syndrome are often the cause of complete heart block. The cause of CHB are Myocarditis, acute myocardial infarction complicated by complete heart block which are transient and restore to normal conduction in 2-3 weeks in inferior wall MI whereas the complete heart block due to anterior wall infarction is extremely difficult treat even with pacemaker implantation.

Electrolyte disorder especially hyperkalemia, Sarcoidosis, Toxic effect of drugs usually Digitalis toxicity etc. Simple noninvasive test like ECG and Holter monitoring can help in the evaluation and diagnosing cardiovascular syncope. Ventricular standstill was thought to be the mechanism responsible for stokes adaams syncope however it can also be due to severe bradycardia, Tachyarrhythmia particularly ventricular tachycardia and ventricular fibrillation. AV blocks are more commonly associated than Ventricular arrhythmias<sup>1,6</sup>.

The medical therapy for complete heart block includes correction of potential contributing factors such as hyperkalemia. The aim of therapy for arrhythmia induced syncope is prompt restoration of circulation during cardiac arrest, restoration of intrinsic cardiac rhythm adequate to maintain cerebral blood flow and prevention of recurrent episodes of syncope. A single stokes adams attack in patient with complete heart block is sufficient reason for pacemaker insertion. Treatment includes immediate cardiopulmonary resuscitation and urgent permanent pacemaker insertion<sup>11</sup>. If undiagnosed (or untreated), Stokes–Adams attacks have a 50% mortality within a year of the first episode. The prognosis following treatment is very good

## Reference

1. Harbison J, Newton JL, Seifer C, et al; Stokes Adams attacks and cardiovascular syncope. Lancet. 2002 Jan 12359(9301):158-60.
2. Sayk F, Frimmel M, Dodt C, Busch HJ, Wolfrum S. Transient loss of consciousness: algorithm for the (differential) diagnosis of syncope at emergency department. Med Klin Intensivmed Notfmed. 2019; 114(5): 410-419.
3. Stokes-Adams; Adams-Stokes; Morgagni-Adams-Stokes Attacks"
4. Katz, Jason; Patel, Chetan (2006). Parkland Manual of Inpatient Medicine. Dallas, TX: FA Davis. p. 903.
5. Donald A Dupler (1953) Ventricular arrhythmia and Stokes - Adams syndrome report of a case. Circulation 7: 585-590.
6. <https://www.bmj.com/rapid-response/2011/10/28/mechanisms-syncope-and-stokes-adams-attacks-bradyarrhythmia-asystole-and-treatment>.
7. H. Calkins and D. P. Zipes, "Hypotension and Syncope," In P. Libby, R. O. Bonow and D. L. Mann, Eds., Braunwald's Heart Disease, 7th Edition, Elsevier Saunders, Philadelphia, 2005, pp. 909-919.
8. The Task Force on Syncope, European Society of Cardiology, "Guidelines on Management (Diagnosis and Treatment) of Syncope-Update 2004," Europace, Vol. 6, No. 6, 2004, pp. 467-537.
9. E. M. Bingham, J. T. Dunn, D. Smith, J. Sutcliffe- Goulden, L. J. Reed, P. K. Marsden and S. A. Amiel, "Differential Changes in Brain Glucose

Metabolism During Hypoglycaemia Accompany Loss of Hypoglycaemia Unawareness in Men with Type 1 Diabetes Mellitus: An [11C]-3-O-methyl-D-glucose PET Study,” *Diabetologia*, Vol. 48, No. 10, 2005, pp. 2080-2089.

10. The Task Force for the Diagnosis and Management of Syncope of the European Society of Cardiology (ESC). “Guidelines for the Diagnosis and Management of Syncope,” *European Heart Journal*, Vol. 30, No. 21, 2009, pp. 2631-2671.
11. ACC/AHA/NASPE Guideline Update for Implantation of Cardiac Pacemakers and Antiarrhythmia Devices; American College of Cardiology/American Heart Association Task Force on Practice Guidelines (2002).

© GSJ